

A case of neutrophilic dermatosis who develop palpable purpura during the use of montelukast

Gözde Yıldırım Çetin¹, Hayriye Sayarlıoğlu², Çiğdem Erhan³, Hasan Kahraman⁴, Harun Cıralık⁵, Mehmet Sayarlıoğlu⁶

Abstract

In this case report, we present a female patient with neutrophilic dermatosis (ND) occurring as palpable purpura after using montelukast. Neutrophilic dermatoses (NDs) are characterized by skin lesions in which mature neutrophils are predominantly located in the epidermis and dermis in the absence of any infective pathology. Classification of the NDs is based upon the recognition of clinical and pathologic features, as well as the identification of associated diseases, like Sweet's syndrome, pyoderma gangrenosum, generalized pustular psoriasis, and Behçet's disease. Cutaneous findings in NDs are variable and can include vesiculopustules, plaques, nodules, or ulcerations. Drug-induced NDs are not uncommon, but ND with palpable purpura is uncommon. The current patient appeared with a rare presentation as palpable purpura without vasculitis regarding ND. It is important that this is the first case report.

Key words: Neutrophilic dermatosis, leukotriene receptor antagonist, montelukast

Introduction

Palpable purpura is one of the major clinical findings of vasculitis resulting from inflammation of the small- or medium-sized blood vessels in the skin in rheumatology practice (1). Common vasculitis mimickers are pigmented purpuric dermatoses, macular purpura due to chronic sun exposure, glucocorticoid therapy, trauma, anticoagulants, inflammatory disorders on the lower extremities or other dependent sites, arthropod bites, scurvy, platelet deficiencies or dysfunction, cholesterol emboli, septic emboli, systemic amyloidosis, strongyloidiasis, purpura fulminans, livedoid vasculopathy, and hypercoagulable and thrombotic disorders (2).

The term 'neutrophilic dermatosis' (ND) was initially used by R.D. Sweet in 1964 as 'acute febrile ND' to describe Sweet's syndrome (3). However, over the years, this terminology has been adapted to demonstrate non-infective dermatoses that exhibit a predominantly neutrophilic inflammatory infiltrate and respond promptly to corticosteroid therapy. Largely, dermatoses with associated vasculitis are not included in this spectrum, though some researchers also include them under this broad entity. As histopathology plays a pivotal role in the classification of this group of diseases, which are diverse in their etiology, ND is a histopathological rather than a clinical entity (4).

Cutaneous findings in neutrophilic dermatoses (NDs) are variable and can include vesiculopustules, plaques, nodules, or ulcerations. The pathogenesis of NDs is unknown. It is believed that these disorders represent a state of altered immunologic reactivity (5).

Drug-induced exanthems are the most common cutaneous reactions to drugs, responsible for approximately 90% of all drug rashes. Other common cutaneous drug reactions are urticaria/angioedema, hypersensitivity vasculitis (palpable purpura), exfoliative dermatitis/erythroderma, Stevens-Johnson syndrome, toxic epidermal necrolysis, erythema multiforme, fixed drug eruption, symmetrical drug-related intertriginous and flexural exanthema, phototoxic eruptions, and photoallergic eruptions. Uncommon cutaneous drug reactions are pemphigus, bullous pemphigoid, linear IgA bullous dermatosis, acute generalized exanthematous pustulosis, lichenoid drug eruption (drug-induced lichen planus), alopecia, cutaneous pseudolymphoma, acral chemotherapy reactions, and drug-induced lupus (6).

The current patient appeared with a rare presentation as palpable purpura regarding ND after using montelukast.

Case Presentation

We report a case of a 56-year-old woman with asthma. She had had asthma for over 15 years. She reported taking inhaler salbutamol, salmeterol-fluticasone aerosol, and theophylline capsule in the last 4 years. Oral montelukast (Singulair; Merck Sharp & Dohme (MSD), New Jersey, USA) (10 mg/day) was added to her



1 Department of Rheumatology, Sütçü İmam University Faculty of Medicine, Kahramanmaraş, Turkey

2 Department of Nephrology, Ondokuz Mayıs University Faculty of Medicine, Samsun, Turkey

3 Department of Internal Medicine, Sütçü İmam University Faculty of Medicine, Kahramanmaraş, Turkey

4 Department of Chest Diseases, Sütçü İmam University Faculty of Medicine, Kahramanmaraş, Turkey

5 Department of Pathology, Sütçü İmam University Faculty of Medicine, Kahramanmaraş, Turkey

6 Department of Rheumatology, Ondokuz Mayıs University Faculty of Medicine, Samsun, Turkey

Address for Correspondence:
Gözde Yıldırım Çetin, Department of Rheumatology, Sütçü İmam University Faculty of Medicine, Kahramanmaraş, Turkey

E-mail: gozdeyildirimcetin@gmail.com

Submitted: 15.04.2014

Accepted: 18.05.2014

Copyright 2014 © Medical Research and Education Association

Figure 1. Palpable purpura on the lower extremities 264x220mm

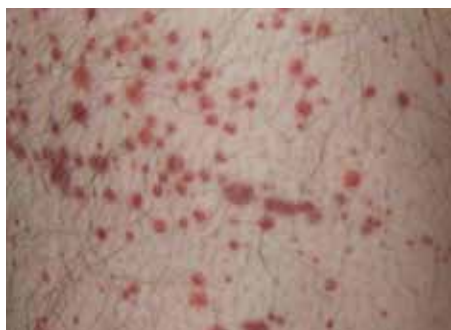
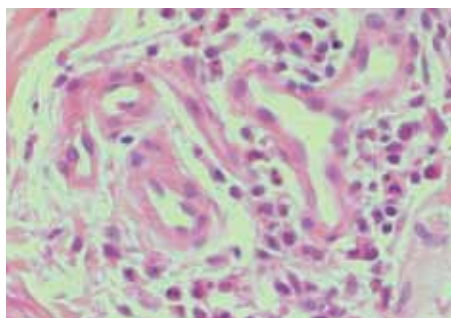


Figure 2. Dense inflammatory infiltrations composed mainly of neutrophils (H&E, X400) 60x45mm



therapy 3 months ago, and she reported using montelukast regularly. She was not using any other medications. She was admitted to the hospital due to lesions on her legs. There was a pruritic and palpable purpuric rash over both lower extremities, and the size of the purpuric skin rash was 2-5 millimeters (Figure 1). The skin of both lower extremities was involved, but the lesions spared the mucosa. Her body temperature and physical examination were normal. We first investigated for the presence of vasculitic diseases, which could be the reason for the purpuric skin rash. There were no positive rheumatologic findings, like Behçet's or inflammatory bowel disease. When we looked at her medical history, she did not have a history of upper respiratory tract disease or renal disease. Laboratory investigations revealed neutrophilia (19.48 cells/mm^3 , normal range: $2-6.9 \text{ cells/mm}^3$). Proteinuria was not found, and p-ANCA and c-ANCA tests, ESR, and CRP (respectively, 30 mm/h , 0.17 mmol/l) were normal. Urine and aerobic and anaerobic blood cultures were negative. At the same time, a skin biopsy of the purpuric lesion was performed. The patient's salbutamol, salmeterol-fluticasone aerosol, and theophylline treatments were continued, but montelukast was discontinued on the second day of admission. At this time, methylprednisolone (40 mg/day iv) was initiated and given for 3 days, followed by oral prednisolone (32 mg/day) for 1 week. The prednisolone dose was tapered by

4 mg/week, and ultimately, prednisolone was stopped. The skin rash improved within 48 h after methylprednisolone treatment. Skin biopsy showed that vessels were seen around a dense accumulation of polymorphonuclear leukocytes. Vascular infiltration of polymorphonuclear leukocytes and fibrin deposition were not seen in the vessel wall (Figure 2). These features support the presence of ND.

The follow-up at 6 months did not show any recurrence of the skin rash. Our investigation revealed that the most probable cause for the purpuric skin lesions was montelukast. This asthmatic patient did not have another coexisting disease, and in the third month of her montelukast treatment, ND appeared.

Discussion

The Naranjo algorithm, or Naranjo scale or Naranjo nomogram, is a questionnaire designed by Naranjo et al. for determining the likelihood of whether an adverse drug reaction (ADR) is actually due to the drug rather than the result of other factors. Probability is assigned via a score, termed definite, probable, possible, or doubtful (7). The score was "5," which means probable ADR.

NDs are characterized by skin lesions in which mature neutrophils are predominantly located in the epidermis, dermis, or appendage in the absence of any infective pathology (8). The non-infectious NDs without vasculitis predominantly involving the epidermis are pustular psoriasis, drug-induced/acute generalized exanthematous pustulosis, keratoderma blennorrhagicum, Sneddon-Wilkinson disease (subcorneal pustulosis), IgA pemphigus (subcorneal pustular dermatosis type, intraepidermal neutrophilic IgA dermatosis-type), antimicrobial pustulosis of the folds, infantile acropustulosis, transient neonatal pustulosis, and those predominantly involving the dermis are Sweet's syndrome, Behçet's disease, pyoderma gangrenosum, bowel-associated dermatosis-arthritis syndrome, inflammatory bowel disease (may also have small vessel vasculitis), neutrophilic eccrine hidradenitis, rheumatoid neutrophilic dermatitis, neutrophilic urticaria, Still's disease, erythema marginatum, and hereditary periodic fever syndrome (8). NDs cover a very broad group of diseases. The prototype of NDs is Sweet syndrome (acute febrile neutrophilic dermatosis). In a study, 77 patients with Sweet syndrome were evaluated. Eighteen patients (23%) reported a preceding infection. A total of 41 (53%) patients were classified as having classic Sweet syndrome, 27 (35%) patients had malignancy-associated Sweet syndrome, and in 9 (12%) patients, drug-induced Sweet syndrome was considered (9). Drug-induced NDs are not uncommon, but ND with palpable purpura is uncommon. We found only one case of ND that was associated with palpable purpura as a drug reaction regarding clomiphene citrate (Clomid), accessed via the PubMed and Google Scholar databases (10). We report a case of ND that was suspected to be caused by montelukast. Montelukast is a leukotriene receptor antagonist. There was no report about leukotriene receptor antagonist-associated ND.

In conclusion, the clinical presentation of vasculitis and ND could appear as purpuric skin rashes. ND should be considered in the differential diagnosis of palpable purpura. In addition, it should be considered that montelukast may cause ND.

Ethics Committee Approval: N/A.

Informed Consent: Written informed consent was obtained from the patient who participated in this study.

Peer-review: Externally peer-reviewed.

Author contributions: Concept - G.Y.C., H.S., C.E.; Design - G.Y.C., H.S., M.S.; Supervision - G.Y.C., H.K., M.S.; Resource - G.Y.C., C.E., H.C.; Materials - G.Y.C., H.S., H.C.; Data Collection&/or Processing - G.Y.C., C.E., H.K.; Analysis&/or Interpretation - G.Y.C., H.S., M.S.; Literature Search - G.Y.C., C.E., M.S.; Writing - G.Y.C., H.S., M.S.; Critical Reviews - G.Y.C., H.S., M.S.

Conflict of Interest: No conflict of interest was declared by the authors.

Financial Disclosure: The authors declared that this study has received no financial support.

References

- Jennette JC, Falk RJ, Andrassy K, Bacon PA, Churg J, Gross WL, et al. Nomenclature of systemic vasculitides. Proposal of an international consensus conference. *Arthritis Rheum* 1994; 37: 187. [CrossRef]
- Fett N, Callen J, Ofori AO. Evaluation of adults with cutaneous lesions of vasculitis. UpToDate. 2014. Available from: www.uptodate.com
- Sweet RD. An acute febrile neutrophilic dermatosis. *Br J Dermatol* 1964; 76: 349-56. [CrossRef]
- Nischal KC, Khopkar U. An approach to the diagnosis of neutrophilic dermatoses: A histopathological perspective. *Indian Journal of Dermatology, Venereology and Leprology*. 2007; 73: 222-30. [CrossRef]
- Moschella SL, Callen J, Ofori AO. Neutrophilic dermatoses. UpToDate. 2014. Available from: www.uptodate.com
- Samel AD, Chu CY, Robert P, Dellavalle RP, Mockenhaupt M, Roujeau JC, et al. Drug eruptions. UpToDate. 2014. Available from: www.uptodate.com
- Naranjo CA, Busto U, Sellers EM, Sandor P, Ruiz I, Roberts EA, et al. A method for estimating the probability of adverse drug reactions. *Clin Pharmacol Ther* 1981; 30: 239-45. [CrossRef]
- von den Driesch P. Sweet syndrome: Acute febrile neutrophilic dermatosis. *J Am Acad Dermatol* 1994; 31: 535-56. [CrossRef]
- Rochet NM, Chavan RN, Cappel MA, Wada DA, Gibson LE. Sweet syndrome: clinical presentation, associations, and response to treatment in 77 patients. *J Am Acad Dermatol* 2013; 69: 557. [CrossRef]
- Coots NV, McCoy CE, Gehlbach DL, Becker LE. A neutrophilic drug reaction to Clomid. *Cutis* 1996; 57: 91-3.