







Orbital inflammation and colitis in pediatric IgG4-related disease: A case report and review of the literature

Lissy Tille¹ , Anja Schnabel¹ , Martin W. Laass¹, Gabriele Hahn², Heike Taut¹, Anna Leszczynska³ , Jessica Pablik⁴ , Reinhard Berner¹ , Normi Brück¹, Christian M. Hedrich^{1,5,6} 

Abstract

IgG4-related disease (IgG4-RD) is an inflammatory disorder characterized by tumor-like swelling in one or more organs, elevated serum IgG4 levels, and histological alterations with infiltration of IgG4-positive plasma cells. IgG4-RD is rare and likely underdiagnosed in children. We report a case of a 16-year-old girl with IgG4-positive colitis that developed weeks after IgG4-related ophthalmic disease and discuss diagnosis and treatment in the context of the literature available. Since the pathophysiology of IgG4-RD is unknown, treatment options are empiric and, for the most part, untargeted. Systemic corticosteroid treatment is the basis of anti-inflammatory treatment in IgG4-RD and induced early remission in our patient. During corticosteroid taper, the patient developed weight loss and intestinal inflammation. Histopathological assessment of the intestinal walls confirmed IgG4-positive colitis. Immune-modulating treatment with non-biologic (e.g., methotrexate (MTX) and mycophenolate mofetil) or biologic (rituximab) disease-modifying antirheumatic drugs has been reported in treatment refractory or corticosteroid-dependent patients. The patient responded to treatment with anti-inflammatory therapy with food rich in TGF- β 2 (modulen) and MTX. This is one of the first pediatric patients reported with IgG4-related colitis extending the phenotype of pediatric IgG4-RD. International collaboration to prospectively document clinical presentation and treatment responses may help to further establish the phenotype and treatment options and to raise awareness for IgG4-RD.

Keywords: IgG4, IgG4-related disease, pediatric, orbital inflammation, colitis

ORCID IDs of the authors:

L.T. 0000-0002-2880-3126;
A.S. 0000-0001-8716-2552;
A.L. 0000-0002-6668-0438;
J.P. 0000-0003-1044-2972;
R.B. 0000-0002-6216-9173;
C.H. 0000-0002-1295-6179.

Cite this article as: Tille L, Schnabel A, Laass MW, Hahn G, Taut H, Leszczynska A, et al. Orbital inflammation and colitis in pediatric IgG4-related disease: A case report and review of the literature. *Eur J Rheumatol* 2020; 7(Suppl 1): S21-S27.

¹ Department of Pediatrics, Medizinische Fakultät Carl Gustav Carus, Technische Universität Dresden, Germany

² Department of Radiology, Medizinische Fakultät Carl Gustav Carus, Technische Universität Dresden, Germany

³ Department of Ophthalmology, Medizinische Fakultät Carl Gustav Carus, Technische Universität Dresden, Germany

⁴ Department of Pathology, Medizinische Fakultät Carl Gustav Carus, Technische Universität Dresden, Germany

⁵ Department of Women's and Children's Health, Institute of Translational Medicine, University of Liverpool School of Life Sciences, Liverpool, UK

⁶ Department of Paediatric Rheumatology, Alder Hey Children's NHS Foundation Trust Hospital, Liverpool, UK

Address for Correspondence:

Christian M. Hedrich; Department of Women's and Children's Health, Institute of Translational Medicine, University of Liverpool School of Life Sciences, Liverpool, UK

E-mail: christian.hedrich@liverpool.ac.uk

Submitted: September 2, 2019

Accepted: October 3, 2019

Available Online Date: December 3, 2019

Copyright©Author(s) - Available online at www.eurjrheumatol.org.

Content of this journal is licensed under a Creative Commons Attribution-NonCommercial 4.0 International License.



Introduction

Idiopathic orbital inflammation syndrome (IOIS) is a rare condition and accounts for approximately 8% of orbital pathologies in childhood (1). IgG4-related disease (IgG4-RD) is a rare fibro-inflammatory entity characterized by infiltration of affected tissues with IgG4-positive plasma cells, elevated serum IgG4, storiform tissue fibrosis, and obliterative phlebitis affecting various organs, including the pancreas, biliary tract, liver, lungs, and/or retroperitoneum (2). IOIS as an initial presentation of an IgG4-RD resembles the most common organ manifestation of IgG4-RD in children (3). Generally, one or more organ systems can be involved in IgG4-RD, and individuals with involvement of two or more organs are diagnosed with systemic IgG4-RD (3). Middle-aged individuals are most commonly affected, but IgG4-RD has been reported across all ages. In children, IgG4-RD is extraordinarily rare and likely underdiagnosed. Approximately 40% of pediatric cases exhibited involvement of systemic disease in few reports published (3). Reflecting that IgG4-RD is a relatively recently identified entity, the underlying pathomechanism, the role of increased serum IgG4, and the potential mechanistic differences between systemic and localized IgG4-RD are not known. The rarity and clinical variability of IgG4-RD affecting awareness among clinicians and the fact that the diagnostic criteria remain controversial significantly complicate the diagnostic process (3). Here, we report a unique case of IgG4-positive colitis in a 16-year-old patient with previously diagnosed IgG4-related IOIS. Clinical findings, diagnostic work-up, and treatment are discussed in the context of the literature available.

Case Presentation

A 16-year-old Caucasian girl was referred to the Department of Pediatrics with suspected orbital cellulitis for further diagnostic procedures and treatment initiation. The patient presented with swelling of the left upper eyelid and conjunctival irritation that had started 10 days prior to admission. Ophthalmological examination showed limited bulbus movement and a hyperemic diffused papilla of the left eye with

normal visual acuity (Figure 1). General clinical examination showed no further pathological findings. The patient did not experience fever and had no personal or family history of malignancy or autoimmune/inflammatory disease.

Magnetic resonance imaging (MRI) using TIRM sequences showed perineural hyperintensity of the left optical nerve and intraorbital muscles, as well as periocular inflammation affecting the left lacrimal gland (Figure 2). Contrast-enhanced T1-weighted fat suppression imaging showed heterogeneous enhancement, suggesting an idiopathic orbital inflammatory disease, excluding lymphoma, cellulitis, or severe optical neuritis (Figure 3).

Routine blood laboratory tests remained largely normal with normal complete blood count and differentiation, slightly elevated erythrocyte sedimentation rate (ESR) of 25 mm within the first hour, normal C-reactive protein (CRP) levels, normal serum lactate dehydrogenase levels, normal uric acid levels, normal free light chain κ/λ ratio, normal angiotensin-converting enzyme levels, and normal C3 and C4 levels. However, elevated serum IgG4 level (3.6 g/l, normal range 0.05-1.96 g/l) was determined. Thyroid function (thyroid-stimulating hormone, triiodothyronine, and free thyroxine) was within the normal range. Antinuclear antibodies (ANAs) were positive (1:640) with a granular pattern. Other autoantibodies tested (antineutrophil cytoplasmic antibodies, peri-

nuclear antineutrophil cytoplasmic antibodies, extractable nuclear antigens, Ro, La, Sm, and U1-RNP) were not detectable. Cerebrospinal fluid examinations remained normal, and infectious disease screening (e.g., Epstein-Barr virus, Cytomegalovirus, Varicella-Zoster virus, Herpes Simplex virus 1/2, *Enterovirus*, *Borrelia*, *Chlamydia*, *Mycoplasma* DNA testing, and interferon gamma release assays for tuberculosis infection) remained normal.

Based on the aforementioned findings from clinical, imaging, and laboratory examinations and significantly elevated IgG4 serum levels, IgG4-related ophthalmic disease was suspected, and systemic anti-inflammatory therapy with oral prednisolone (2 mg/kg/day) was initiated. With anti-inflammatory treatment, ophthalmologic status normalized after 8 weeks, and slow tapering of prednisolone (>4 months) was initiated.

Thereafter, the patient was followed up by the pediatric rheumatology department as an out-patient every 3 months. She reported weight loss of 11 kg over the past 6-8 months (body mass index 15 kg/m²), lack of appetite, and upper gastric pain, as well as amenorrhea, 9 months after the initial manifestation. She denied stool irregularities or fever. Symptoms first began, but had been ignored and not shared, after oral prednisolone therapy was initiated but persisted after discontinuation of treatment. Laboratory findings showed mild leukopenia (2.8 Gpt/l, normal range 3.8-9.8 Gpt/l) and increased CRP (11 mg/l, normal range <5 mg/l) and ESR (25 mm within the first hour). Serum IgG4 (2.3 g/l) and ANA (1:1280, granular pattern) remained elevated. Fecal calprotectin was elevated (1120 $\mu\text{g/g}$, normal: <50 $\mu\text{g/g}$) and suggested intestinal inflammation. A dihydrorhodamine oxidative burst tests delivered normal results and no evidence of chronic granulomatous disease/septic granulomatosis. Anti-endomysium autoantibodies (for celiac disease) were negative.

Ultrasonography unveiled diffuse intestinal wall thickening and signal hyperechogenicity of the terminal ileum and cecum (4.3 mm) and inflammatory involvement of the attached mesenteries (Figure 4). MRI showed mild but generalized contrast enhancement of the small intestines and the colon (Figure 5). Video capsule endoscopy unveiled many ulcers in the distal third of the small bowel. Colonoscopy showed inflammatory changes of the entire colon (Figure 6). Tissue biopsies from the colon unveiled inflammatory infiltrates, crypt abscesses, activated lymph follicles in the mucosal layer, and infiltrates of IgG4-positive plasma

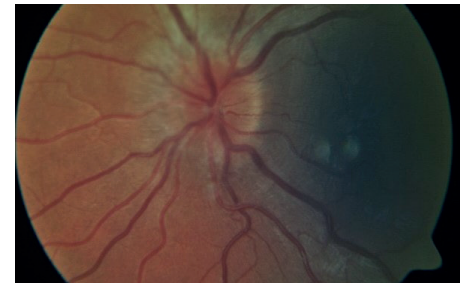


Figure 1. Unilateral optic disc edema and hyperemia with neuronal swelling, blurred disc margin, venous dilation and flow stasis, and absence of the venous pulsation of the affected left eye.

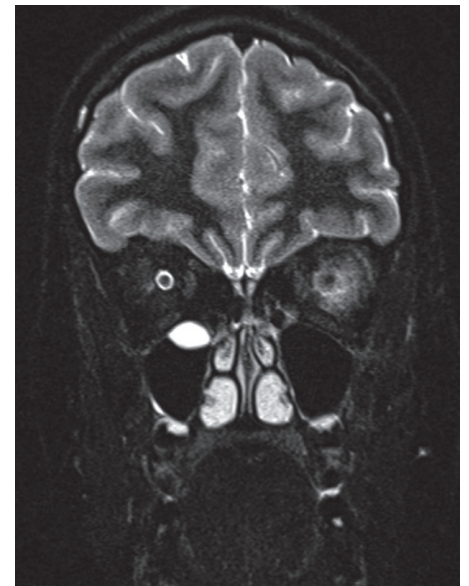


Figure 2. MRI orbital. Coronal TIRM sequence shows left high signal perineural, retrobulbar, and peribulbar and in the glandula lacrimalis.

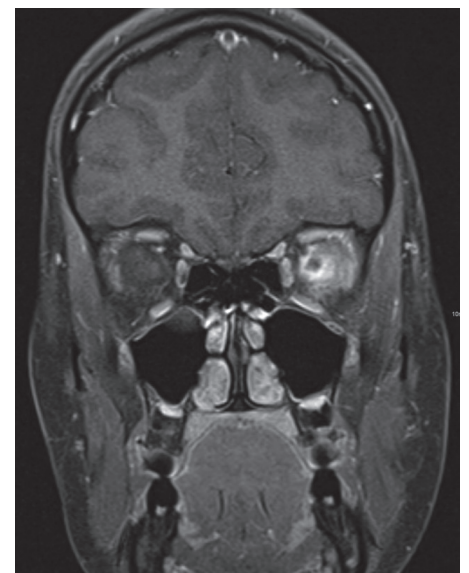

Figure 3. MRI orbital. Coronal T1-weighted image after contrast with fat saturation shows left enhancement retrobulbar and perineural involving the muscles.

Main Points

- Diagnosing IgG4-RD in children can be challenging because of its rarity, variable presentations, and multiple differential diagnoses.
- Idiopathic orbital inflammation syndrome resembles the most common organ manifestation of IgG4-RD in children.
- Available consensus criteria for the diagnosis of IgG4-RD are validated only in adults, and there are no studies available analyzing IgG4-RD in children.
- Treatment is not standardized and based on personal experience, small case series, and expert opinion.
- Corticosteroids are usually the basis of treatment, and disease-modifying antirheumatic drugs or B cell depletion may be used in severe or refractory cases.
- The case presented here extends the phenotype of pediatric IgG4-RD by intestinal inflammation (colitis).

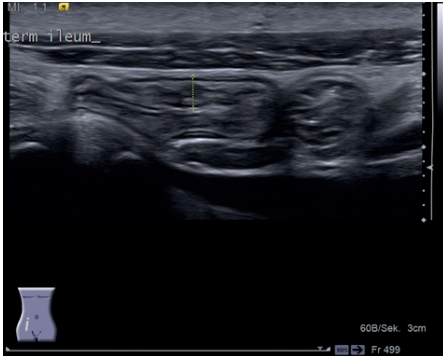


Figure 4. Ultrasonography showing intestinal wall thickening, diffuse layering of the terminal ileum (4.3 mm), and an inflammatory reaction of the attached mesenteric.

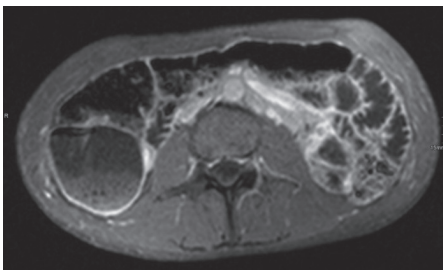


Figure 5. MRI abdomen. Transversal T1-weighted image after contrast with fat saturation shows mild enhancement of the wall of the colon and small intestines.

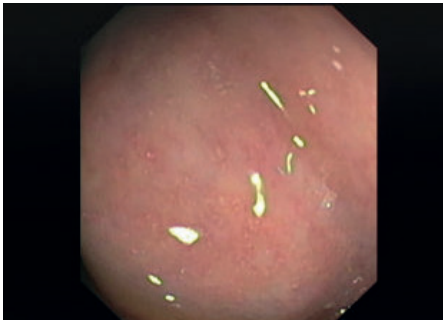

Figure 6. Colonoscopy. Active colitis, erosions with fibrin exudates, erythema, and near complete loss of normal vascular pattern.

cells (>10 IgG4-positive plasma cells/standard HPF) (Figure 7). There was no evidence of neoplasia or infection.

In the context of pre-existing IgG4-related orbital disease, the findings were interpreted as a new manifestation of (now systemic) IgG4-RD. Anti-inflammatory nutritional therapy with food rich in TGF- β 2 (Modulen) and systemic immunomodulatory therapy with methotrexate (MTX) were suggested, but initially denied by the patient. Owing to persisting symptoms, increasing fecal calprotectin (>2000 μ g/g), progressive intestinal wall changes on ultrasound, and persisting inflammatory alterations of the esophagus and gastric mucosa on endoscop-

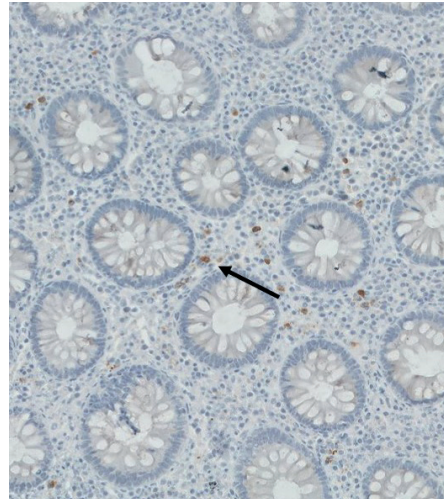


Figure 7. Immunohistochemistry of a colon biopsy (40x). Inflammatory infiltrate in the mucosal layer, rich in IgG4-positive plasma cells (marked with arrow) (>10 IgG4-positive plasma cells/HPF).

ic re-evaluation (8 weeks later), the patient agreed to treatment with Modulen (2.5-3 l/day for 8 weeks) and MTX (12.7 mg/m²). As a result, symptoms improved (including weight gain of 3.5 kg in 2 months, 8% of body weight), and inflammatory laboratory parameters (CRP and ESR) normalized. Nevertheless, serum levels of IgG4 remained elevated (2.7 g/l).

Unfortunately, further consultations in our pediatric rheumatology department were canceled, medication with MTX was discontinued after 3 months of treatment, and the patient was lost to follow-up.

Literature Review and Discussion

Epidemiology and clinical picture

Though overall rare, inflammatory orbital disease is the most common organ manifestation of IgG4-RD in children (3). IgG4-RD was first described in 2003 as a clinical entity that is characterized by systemic fibrotic inflammation (4). To our knowledge, there are no retrospective or prospective studies available investigating children with IgG4-RD. Several reports discussed individual cases of childhood IgG4-RD (5-7). Karim et al. (3) reviewed published pediatric cases and found that the median age at onset is approximately 13 (3-16) years, and that approximately 2/3 (64%) of cases affect girls and young women. Patients developed tumorous lesions that initially raised the suspicion of malignancy in a substantial subset of cases.

Distribution of organ manifestations in IgG4-RD is comparable between children and adults. Generally, all organs can be involved, whereas the orbit, pancreas, biliary ducts, bronchopul-

monary system, thyroid, salivary glands, lymph nodes, and mesenteries are most commonly affected (3). Inflammation of the orbital region can manifest as ocular myositis, dacryoadenitis, perineuritis of the optic nerve, and orbital inflammatory pseudotumor (8).

Pathophysiology

The pathophysiology of IgG4-RD is unknown as briefly mentioned in the Introduction section. Ongoing inflammation in IgG4-RD results in progressive fibrosis and irreversible organ damage (4). Several pathophysiological concepts have been proposed. Currently unknown immunologic trigger mechanisms (e.g., foreign pathogen- and/or damage-associated molecular patterns) may activate innate immune cells, mainly monocytes and basophils, which in turn induce adaptive immune responses including B cell activation and IgG4 production (8). A number of infectious pathogens have been suggested as potential immunologic triggers in IgG4-RD, including *Helicobacter pylori* (9), pulmonary *Paragonimus westermani* infections, and/or in helminth infections. However, no specific pathogen-associated molecular patterns contributing to IgG4-RD have yet been identified. Activated basophils may enhance T helper subset 2 (Th2) cell-driven inflammation. Increased numbers of Th2 lymphocytes and regulatory T cells (Treg) have been observed in peripheral blood of patients with IgG4-RD, and tissue sections from patients showed increased expression of Th2- and Treg-associated cytokines interleukin (IL)-5, IL-13, IL-10, and transforming growth factor (TGF)- β (4). Pathologically activated Th2 lymphocytes may result in the recruitment of Treg cells which secrete IL-10 and TGF- β , cytokines that mediate fibroblast activation resulting in tissue fibrosis (4, 10). Finally, the role of IgG4 antibodies in the pathogenesis remains unclear (effector vs. by-product). Since it is mainly viewed as an anti-inflammatory molecule, the direct involvement of IgG4 in organ inflammation is currently debated (8, 11).

Diagnosis of IgG4-RD

Based on the rarity of IgG4-RD and associated low awareness among providers, diagnosing IgG4-RD can be challenging, and cases may be missed. A set of diagnostic criteria for IgG4-RD was proposed following a consensus process by Umehara et al. (12), which can be applied after exclusion of important differential diagnoses (e.g., cancers, systemic vasculitis, and sarcoidosis) (Figure 8). However, criteria were proposed based on experience in adult Japanese cohorts and (to our knowledge) have not been tested prospectively in Asian or non-Asian

populations. Therefore, their diagnostic value, particularly in Caucasian patients, remains unknown. Deshpande et al. (13) suggested a

pathology score for IgG4-RD also based on a consensus process (Figure 9). They emphasize that on the one hand, histopathological criteria

provide evidence for the diagnosis, but on the other hand, need to be correlated with clinical and radiographic characteristics to ensure the diagnosis (13). They place more emphasis on appropriate morphological features and suggest that >10 IgG4+ plasma cells/HPF are required to secure the diagnosis of IgG4-RD, but for example (especially depending on the organs involved), IgG4+/IgG+ plasma cell ratios <40% do not exclude IgG4-RD. On the other hand, a number of non-IgG4-RD entities can be associated with IgG4+/IgG+ plasma cell ratios >40%. Of note, conditions associated with elevated serum IL-6 concentrations, such as Castleman's disease, rheumatoid arthritis, and other immune-mediated conditions, may also exhibit increased numbers of IgG4+ plasma cells, tissue IgG4+/IgG+ plasma cell ratios >40%, and elevated serum IgG4 concentrations (14, 15).

In daily practice, the diagnosis of IgG4-RD may be suspected in patients with swelling or mass in one or more organs on clinical examination and/or diagnostic imaging in the context of elevated serum IgG4 (>1.35 g/l). However, the positive predictive value of elevated serum IgG4 is limited since a significant proportion of children exhibit (at least mildly) elevated serum IgG4 levels (up to 70%). Similar observations have been made in the adult population (up to 30%-50%) (3, 16).

Thus, histopathology and associated aforementioned scores play a central role in diag-

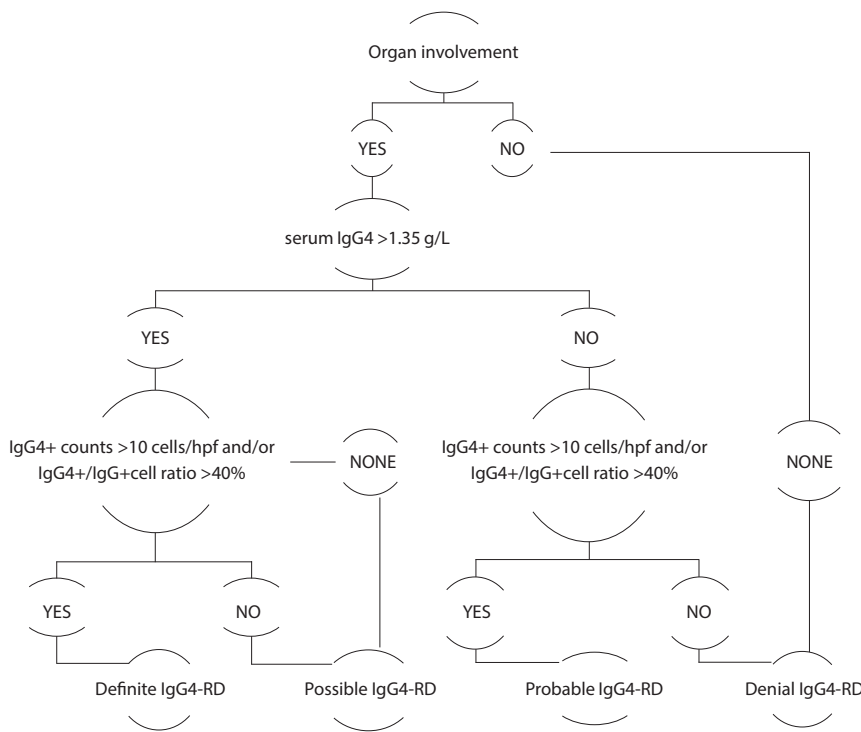


Figure 8. Diagnostic criteria for IgG4-RD as proposed by Umehara et al (8, 13).

Consensus on the pathology of IgG4-RD			
Histologically Highly Suggestive for IgG4-RD	Probable Histological Features of IgG4-RD	Minimal Criteria to Propose Involvement of New Organ in IgG4-RD	Insufficient Histopathological Evidence of IgG4-Related Disease
2 out of 3 histological features fulfilled: (1) dense lympho-plasmacytic infiltrate (2) storiform fibrosis (3) obliterative phlebitis AND positive IgG4 immunostain: IgG4+ counts >10 cells/hpf and IgG4+/IgG+ cell ratio >40%	Single histopathological feature fulfilled or lack of complete immunohistochemical profile (e.g. dense lymphoplasmacytic infiltrate and required numbers of IgG4 cells) AND additional serological (serum IgG4 >1.35 g/L) or clinical or radiological criteria (e.g. other organ involvement)	(1) Characteristic histopathological findings AND IgG4+ plasma cells & IgG4+/IgG+ ratio AND (2) Serum IgG4 >1.35 g/L AND (3) Effective response to glucocorticoid therapy AND (4) Reports of other organ involvement consistent with IgG4-RD	Cases outside other categories

Figure 9. Diagnostic terminology for IgG4-related disease as suggested by Deshpande et al. (14).

Criteria of patient reported	1. Diffuse or localized swelling or masses in one or multiple organs	✓ Orbital inflammation syndrome
	2. Serum IgG4-Concentration >1.35 g/L	✓ 3.7 g/L
	3. Histopathological criteria (Deshpande et al. (14)) - Lymphocyte and plasma-cell infiltration - Tissue fibrosis - Obliterative phlebitis - >10 IgG4+ plasma cells/hpf - IgG4+/IgG-plasma cell ratio >40%	✓ - - - ✓ >10 IgG4+ plasma cells/hpf -> Probable histological IgG4-RD -
	4. Diagnostic criteria (Umehara et al. (13)) a) Definite IgG4-RD b) Possible IgG4-RD c) Probable IgG4-RD	- ✓ -
	5. Response to glucocorticoid therapy	✓
	6. Exclusion of differential diagnoses, e.g. malignant tumors (cancer or lymphoma), granulomatosis with polyangiitis, sarcoidosis	✓

Figure 10. Summarized diagnostic and histopathological criteria for IgG4-related disease by Umehara et al. (13) and Deshpande et al. (14). Criteria met by the index patient are marked with a checkmark.

nosing IgG4-RD. In addition to IgG4-positive plasma cells, storiform fibrosis and obliterative phlebitis can be present and are predominant in pancreatic manifestations of IgG4-RD. However, fibrosis and angiopathy are rarely observed in intestinal lesions or lymph nodes (17). Indeed, the diagnostic criteria published by Umehara et al. (12) did not include gastrointestinal diseases as part of IgG4-RD. Disease-associated intestinal inflammation has been established as part of IgG4-RD since then that usually does not entail mass-like formations, dense fibrosis, or obliterative phlebitis, all of which are considered histopathological characteristics that are required to be met to make a diagnosis based on the criteria proposed by Deshpande et al. (13, 18).

IgG4-positive plasma cells can be present in inflamed tissues from patients with differential diagnoses that share symptoms with IgG4-RD and may also present with elevated IgG4 serum levels, thereby further complicating the situation. Thus, alternative diagnosis (e.g., xanthogranulomatous disease, granulomatosis with polyangiitis, and sarcoidosis), required to be thoroughly excluded before the diagnosis of IgG4-RD, is made (19). Few studies detected high levels of mucosal and serum IgG4 in patients with inflammatory bowel disease (IBD) (17). Thus, it is matter of debate whether increased serum IgG4 and (isolated) intesti-

nal infiltration with IgG4-positive plasma cells should trigger the diagnosis of IgG4-RD rather than other "classical" forms of IBD (20). Finally, since IgG4-positive plasma cell infiltrates can be seen in tissues surrounding cancer cells and IgG4-RD is characterized by tumorous swelling, malignancies required to be considered and excluded before the diagnosis of IgG4-RD can be made (4).

Our patient initially presented with singular solid-organ inflammatory disease of the orbit. Owing to diffuse inflammation affecting the optical nerve and surrounding musculature, we decided not to conduct surgical interventions to collect tissue for histopathology. Development of inflammatory symptoms in the gastrointestinal tract after an initially successful corticosteroid treatment controlling intra-orbital inflammation resulted in classification as systemic IgG4-RD. Indeed, histopathological assessment of the intestinal walls delivered dense inflammatory infiltrates with lymph follicles in the mucosal layer that were rich in IgG4-positive plasma cells with >10 IgG4-positive plasma cells/HPF. However, we did not see an IgG4/IgG plasma cell ratio >40%. While this may offer room for debate considering the diagnostic criteria suggested by Umehara et al. (12), Deshpande et al. (13) consider an IgG4/IgG plasma cell ratio <40% as insufficient to exclude IgG4-RD (21). Indeed, we feel that the

diagnosis of IgG4-RD is justified based on idiopathic orbital inflammation, significantly elevated serum IgG4 levels, intestinal involvement with increased IgG4-positive plasma cell numbers, and rapid response to immune-modulating treatment (see below) (Figure 10).

Treatment

Treatment of IgG4-RD is empiric and based on personal experience of healthcare professionals, expert opinion, case reports, and retrospective case series. Usually, treatment decisions are adapted toward the site of inflammation and the extent of organ involvement. In the past, clinically "mild" single organ involvement usually triggered clinical follow-up without anti-inflammatory treatment. More recently, "mild" manifestations have been considered early disease stages, and anti-inflammatory treatment is usually offered to all patients with IgG4-RD (3). More severe cases ask for a rapid introduction of immune-modulating therapy. Corticosteroids, usually prednisone or prednisolone, are used for first-line therapy. However, there is no consensus on dose or treatment duration. Karim et al. (3) suggested oral prednisolone (0.5-2 mg/kg/day) to induce rapid remission, followed by a slow taper over 3-6 months to avoid relapse of disease. Non-biologic disease-modifying antirheumatic drugs (DMARDs), including mycophenolate mofetil, azathioprine, or MTX, have been suggested

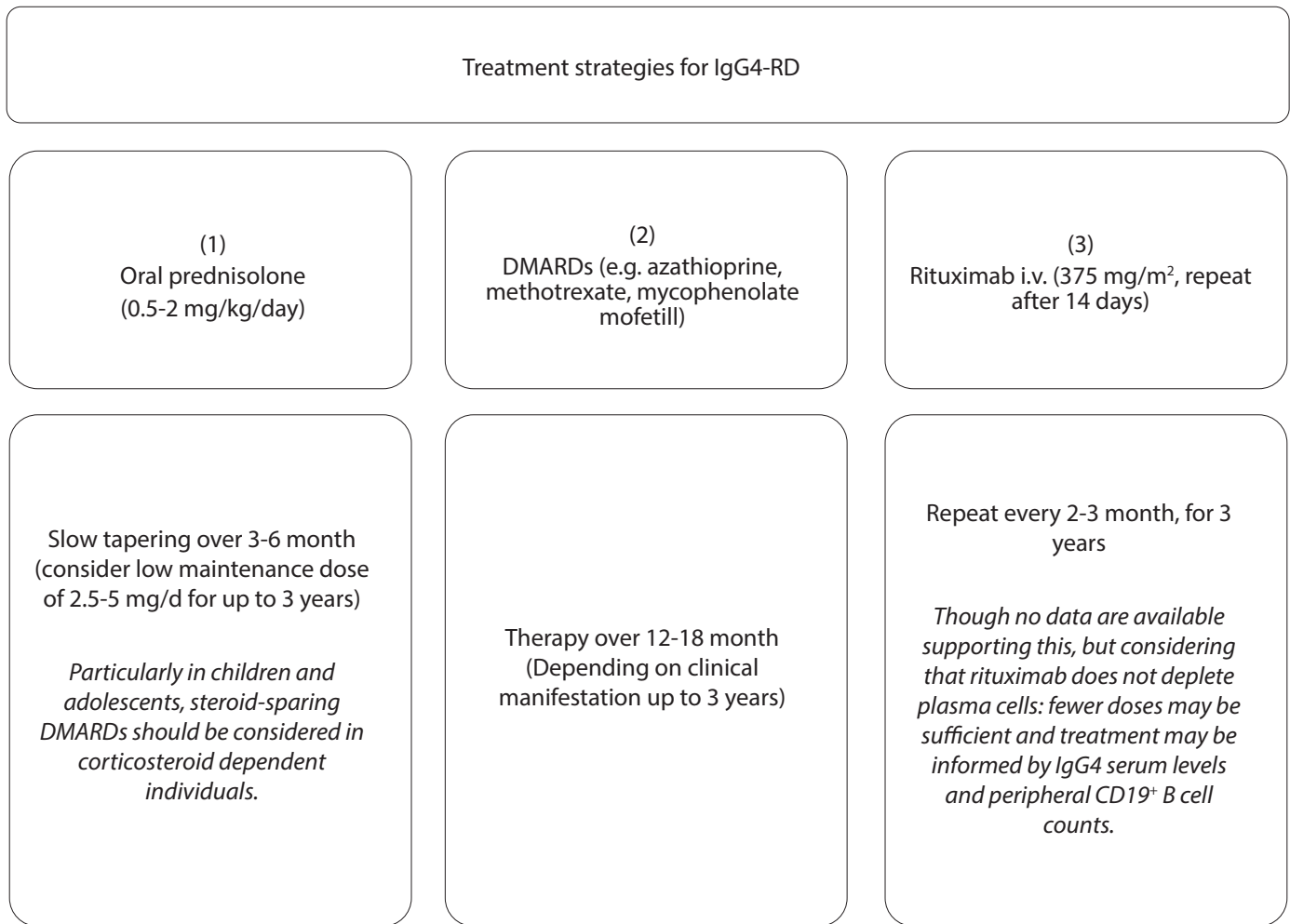


Figure 11. Treatment options in IgG4-RD (3). Comments from the authors of this manuscript are shown in italics.

as steroid-sparing agents and/or in patients refractory to corticosteroids alone (22). Caruthers et al. (23) evaluated rituximab as a treatment alternative for resistant cases in adults. Out of 30 IgG4-RD patients treated with two doses of rituximab (1000 mg each), a total of 97% responded to therapy, 77% achieved the primary outcome (reduced disease activity off corticosteroids), and 47% reached complete remission (Figure 11).

Our patient initially received treatment with oral prednisolone (2 mg/kg/day) to control intraorbital inflammation. Subsequent inflammatory involvement of the intestine resulted in re-establishment of immune-modulating treatment with corticosteroids now accompanied with Modulen and MTX. Early response to treatment resulted in normalized inflammatory parameters and weight gain within weeks.

Published data on treatment duration and disease monitoring are limited. For disease monitoring, imaging (ultrasonography or MRI) of affected organs is essential, whereas moni-

toring of serum IgG4 levels has not been validated (4). Unfortunately, the patient was lost to follow-up 3 months after remission induction and decided to discontinue treatment. Thus, we cannot report long-term outcomes.

Conclusion

To our knowledge, this is the first report of a pediatric patient with a combination of orbital and intestinal involvement in IgG4-RD. Healthcare providers should consider IgG4-RD in cases of otherwise unexplained inflammatory alteration or tumorous lesions. The rarity of disease particularly in childhood and variable clinical presentations contribute to diagnostic delay, underdiagnoses, and/or even misdiagnoses. Early diagnosis and treatment are essential to minimize organ damage. Treatment with corticosteroids is usually effective, but maintenance therapy with non-biologic and/or biologic DMARDs may be required. International collaboration is needed to produce reliable data in this rare condition and to validate the proposed diagnostic criteria and treatment options for children (but also adults) with IgG4-RD.

Peer-review: Externally peer-reviewed.

Author Contributions: Concept - L.T., A.S., C.M.H.; Design - L.T., C.M.H.; Supervision - C.M.H.; Resources - L.T., A.S., M.W.L., G.H., H.T., A.L., J.P., R.B., N.B., C.M.H.; Materials - A.S., M.W.L., G.H., H.T., A.L., J.P.; Data Collection and/or Processing - L.T., A.S., C.M.H.; Analysis and/or Interpretation - L.T., A.S., M.W.L., G.H., H.T., A.L., J.P., R.B., N.B., C.M.H.; Literature Search - L.T., C.M.H.; Writing Manuscript - L.T., C.M.H.; Critical Review - L.T., A.S., M.W.L., G.H., H.T., A.L., J.P., R.B., N.B., C.M.H.

Conflict of Interest: The authors have no conflict of interest to declare.

Financial Disclosure: The authors declared that this study has received no financial support.

References

- Bau V, Röpke E, Marquardt L. Idiopathische orbitale Entzündung im Kindesalter - Fallbericht und Literaturreview TT - Idiopathic Orbital Inflammation Syndrome in Childhood - Case Report and Literature Review. *Klin Monatsbl Augenheilkd* 2010; 227: 760-4. [\[CrossRef\]](#)
- Navaneethan U, Venkatesh PGK, Kapoor S, Kiran RP, Remzi FH, Shen B. Elevated Serum IgG4 is Associated with Chronic Antibiotic-Refractory

- Pouchitis. *J Gastrointest Surg* 2011; 15: 1556-61. [\[CrossRef\]](#)
3. Karim F, Loeffen J, Bramer W, Westenberg L, Verdijk R, van Hagen M, et al. IgG4-related disease: A systematic review of this unrecognized disease in pediatrics. *Pediatr Rheumatol* 2016; 14: 1-9. [\[CrossRef\]](#)
 4. Kamisawa T, Zen Y, Pillai S, Stone JH. IgG4-related disease. *Lancet* 2015; 385: 1460-71. [\[CrossRef\]](#)
 5. Hasosah MY, Satti MB, Yousef YA, Alzahrani DM, Almutairi SA, Alshahfi AF, et al. Case Report IgG4-related Sclerosing Mesenteritis in a 7-year-old Saudi Girl. *Saudi J Gastroenterol* 2014; 20: 385-8. [\[CrossRef\]](#)
 6. Naghibi M, Ahmed A, al Badri AM, Bateman AC, Shepherd HA, Gordon JN. The successful treatment of IgG4-positive colitis with adalimumab in a patient with IgG4-related sclerosing disease - a new subtype of aggressive colitis? *J Crohn's Colitis* 2013; 7: e81-e84. [\[CrossRef\]](#)
 7. Batu ED, Arici ZS, Orhan D, Kiratli H, Ozen S. Immunoglobulin G4-related orbital disease: A report of two paediatric cases. *Clin Exp Rheumatol* 2015; 33: 409-10.
 8. Yamamoto M, Takahashi H, Shinomura Y. Mechanisms and assessment of IgG4-related disease: Lessons for the rheumatologist. *Nat Rev Rheumatol* 2014; 10: 148-59. [\[CrossRef\]](#)
 9. Frulloni L, Lunardi C, Simone R, Dolcino M, Scattolini C, Falconi M, et al. Identification of a novel antibody associated with autoimmune pancreatitis. *N Engl J Med* 2009; 361: 2135-42. [\[CrossRef\]](#)
 10. Watanabe T, Yamashita K, Fujikawa S, Sakurai T, Kudo M, Shiokawa M, et al. Involvement of activation of toll-like receptors and nucleotide-binding oligomerization domain-like receptors in enhanced IgG4 responses in autoimmune pancreatitis. *Arthritis Rheum* 2012; 64: 914-24. [\[CrossRef\]](#)
 11. Weindorf SC, Frederiksen JK. IgG4-related disease: A reminder for practicing pathologists. *Arch Pathol Lab Med* 2017; 141: 1476-83. [\[CrossRef\]](#)
 12. Umehara H, Okazaki K, Masaki Y, Kawano M, Yamamoto M, Saeki T, et al. Comprehensive diagnostic criteria for IgG4-related disease. *Mod Rheumatol* 2012; 22: 21-30. [\[CrossRef\]](#)
 13. Deshpande V, Zen Y, Chan JKC, Yi EE, Sato Y, Yoshino T, et al. Consensus statement on the pathology of IgG4-related disease. *Mod Pathol* 2012; 25: 1181-92. [\[CrossRef\]](#)
 14. Sato Y, Kojima M, Takata K, Morito T, Mizobuchi K, Tanaka T, et al. Multicentric Castleman's disease with abundant IgG4-positive cells: a clinical and pathological analysis of six cases. *J Clin Pathol* 2010; 63: 1084-9. [\[CrossRef\]](#)
 15. Strehl JD, Hartmann A, Agaimy A. Numerous IgG4-positive plasma cells are ubiquitous in diverse localized non-specific chronic inflammatory conditions and need to be distinguished from IgG4-related systemic disorders. *J Clin Pathol* 2011; 64: 237-43. [\[CrossRef\]](#)
 16. Pieringer H, Parzer I, Wohrer A, Reis P, Oppl B, Zwerina J. IgG4-related disease: An orphan disease with many faces. *Orphanet J Rare Dis* 2014; 9: 1-14. [\[CrossRef\]](#)
 17. Koizumi S, Kamisawa T, Kuruma S, Tabata T, Chiba K, Iwasaki S, et al. Immunoglobulin G4-related gastrointestinal diseases, are they immunoglobulin G4-related diseases? *World J Gastroenterol* 2013; 19: 5769-74. [\[CrossRef\]](#)
 18. Harada A, Torisu T, Sakuma T, Esaki M. A case of duodenal bulb involvement of Immunoglobulin G4 related disease complicated by ulcerative colitis. *Dig Liver Dis* 2018; 50: 515. [\[CrossRef\]](#)
 19. Verdijk RM, Heidari P, Verschooten R, van Daele PL, Simonsz HJ, Paridaens D. Raised numbers of IgG4-positive plasma cells are a common histopathological finding in orbital xanthogranulomatous disease. *Orbit* 2014; 33: 17-22. [\[CrossRef\]](#)
 20. Faria RJ, Clemente CM, Carneiro FP, Santos-Neto L. Can IgG4 Levels Identify the Ulcerative Colitis Subtype of Inflammatory Bowel Disease? *Gastroenterol Res* 2015; 8: 178-85. [\[CrossRef\]](#)
 21. Brown RA, Henderlight M, Do T, Yasin S, Grom AA, DeLay M, et al. Neutrophils From Children With Systemic Juvenile Idiopathic Arthritis Exhibit Persistent Proinflammatory Activation Despite Long-Standing Clinically Inactive Disease. *Front Immunol* 2018; 9: 2995. [\[CrossRef\]](#)
 22. Khosroshahi A, Wallace ZS, Crowe JL, Akamizu T, Azumi A, Carruthers MN, et al. International consensus guidance statement on the management and treatment of IgG4-related disease. *Arthritis Rheumatol* 2015; 67: 1688-99. [\[CrossRef\]](#)
 23. Carruthers MN, Topazian MD, Khosroshahi A, Witzig TE, Wallace ZS, Hart PA, et al. Rituximab for IgG4-related disease: a prospective, open-label trial. *Ann Rheum Dis* 2015; 74: 1171-7. [\[CrossRef\]](#)